



(RESEARCH ARTICLE)



Gene therapy for spinal muscular atrophy (SMA): First experience with Onasemnogene abeparvovec (Zolgensma®) in a private hospital in Mexico

José Antonio Infante Cantú and Sofía Lucila Rodríguez Rivera *

Tecnologico de Monterrey. Zambrano Hellion TecSalud Hospital, Pediatric Neurology Institute, Nuevo Leon, Mexico.

International Journal of Science and Research Archive, 2024 11(02), 1067–1072

Publication history: Received on 22 February 2024; revised on 30 March 2024; accepted on 02 April 2024

Article DOI: <https://doi.org/10.30574/ijrsra.2024.11.2.0549>

Abstract

Spinal muscular atrophy is a hereditary neuromuscular disease characterized by the degeneration of alpha motor neurons of the anterior horn of the spinal cord, leading to progressive symmetrical muscle weakness and a high risk for respiratory complications resulting in the need for some degree of ventilatory support.

Two infants are presented with hypotonic syndrome in which spinal muscular atrophy was diagnosed by a genetic study. Gene therapy with Zolgensma® was used to evaluate the clinical improvement in motor function according to the Chop Intend Scale.

Keywords: Spinal muscular atrophy; Genetic therapy; Motor scale; SMN Protein; Onasemnogene abeparvovec

1. Introduction

Spinal muscular atrophy (SMA) is a genetic disease that causes weakness and wasting in the voluntary muscles of infants and children and, more rarely, in adults¹.

It is identified as the loss of lower motor neurons in the spinal cord and brainstem, leading to progressive symmetrical muscle weakness².

Specifically, it is an autosomal recessive disorder in the survival motor neuron 1 gene, SMN1, that causes a loss of specialized nerve cells, termed alpha motor neurons that control muscle movement.

The SMN protein codes for 2 genes (SMN1 y SMN2). It is vital for its role in the spliceosome assembly and biogenesis of ribonucleoproteins. A loss of the SMN protein affects the motor neuron's homeostatic environment³. A loss of these motor neurons prevents the sending of signals between the spinal cord and skeletal muscle, resulting in progressive proximal muscle weakness and paralysis⁴.

The SMA phenotype is categorized into four grades of severity (SMA I, SMA II, SMA III, SMA IV) based on the age of onset and motor function achieved⁵. Type 1 is the most severe, where the patient is unable to sit; Type 2 is unable to walk unaided; Type 3 can achieve some walking abilities; and Type 4 is adult-onset SMA^{6,7}.

When mutations occur in the SMN1 gene, the amount of encoded protein practically disappears, since the levels of a protein that the SMN2 gene can provide are not sufficient. The more copies of the SMN2 gene the patient has, the less severe the disease.

* Corresponding author: Sofía Lucila Rodríguez Rivera e-mail sofiardz85@gmail.com

SMN2 copy amount largely accounts for the clinical severity between the SMA types. The higher the amount of SMN2 copy mutation (with fewer copies) the higher the probability of developing a severe phenotype.

When untreated, it will result in severe limitations to motor function, including walking incapability; high risk for respiratory complications resulting in the need for some degree of ventilatory support; as well as a high risk for orthopedic complications such as frequently painful contractures and scoliosis; and reduced life expectancy.

The 45% to 60% of cases of SMA are SMA Type 1, making it the most common form of SMA⁸. Patients with SMA Type 1 with 2 copies of SMN2 have a particularly poor prognosis. These patients usually show signs of SMA before six months of age, evident by their lack of ability to sit. Unfortunately, these infants typically do not survive past two years of age without significant mechanical ventilatory and nutritional support.

The diagnosis of SMA can be confirmed with molecular genetic testing with targeted mutation analysis⁹.

Gene therapy is an experimental approach that uses imported genes to treat disorders that result from genetic mutations¹⁰. Gene therapies include replacing, silencing, or knocking out a mutated gene or introducing a new gene to restore additional function or protection.

Onasemnogene abeparvovec, also known as Zolgensma®, is a gene therapy that was recently approved by the US Food and Drug Administration in May 2019 as a treatment for SMA in pediatric patients under the age of two.

It consists of a single-dose, free-of-preservative, sterile, intravenous infusion of a non-replicating, self-complementary adeno-associated vector 9 (AAV9) that crosses the blood-brain barrier. The active substance in Zolgensma® contains a functional copy of the SMN1 gene under the control of the cytomegalovirus (CMV) enhancer/chicken- β -actin-hybrid promoter (CB)¹¹.

One of the two adeno-associated vectors (AAV) inverted terminal repeats (ITRs) has been modified to promote intramolecular annealing of the transgene, thus forming a double-stranded transgene ready for transcription. Therefore, restoring a normal SMN protein regulates cellular homeostatic pathways and, by extension, the state of the motor neuron.

Chop Intend Scale (Children's Hospital of Philadelphia Infant Test of Neuromuscular Disorders)¹²

A 64-point motor assessment that captures neck, trunk, proximal, and distal limb strength in 14 elicited and 2 observational items are designed to evaluate muscle strength and function in infants with SMA.

Each item is graded on a scale of 0 to 4 (0 = no response, 4 = complete response).

The total score ranges from 0 to 64. Higher scores indicate improved ability.

The objective was to study two patients with SMA in whom gene therapy is applied with Onasemnogene abeparvovec, also known as Zolgensma®.

2. Clinical case 1

4-month-old girl, with normal pregnancy, obtained by natural childbirth, without complications. She is brought to the consultation due to hypotonia at one month of age. On neurological examination, expressive facies, with visual tracking and social smile, lingual fasciculations, hypotonia, and weakness of the 4 extremities predominantly proximal, with Daniels Scale 3/5 muscle strength, as well as areflexia, were detected. Her breathing was with thoraco-abdominal dissociation, without oxygen requirement.

Genetic testing for MLPA was requested, resulting in 0 copies of the exon 7 SMN1 gene, 1 copy of the exon 8 SMN1 gene, and 2 copies of the SMN2 gene. She was diagnosed with spinal muscular atrophy type 1 due to the onset of symptoms and genetic confirmation at four months of age.

Subsequently, anti-AAV9 antibodies were requested; they were negative with a titer <1:50. Normal liver function tests and blood counts were taken.

During her evolution, she presented respiratory infection due to rhinovirus with increased secretions, which were managed with pulmonary physiotherapy. Currently having difficulty swallowing with the use of a nasogastric tube.

The Chop Intend Scale was 37 (moderate grade) before treatment (Fig. 1).

Onasemnogene abeparvovec, also known as Zolgensma®, is applied at five months of age, in the operating room, in a sterile environment, during one hour with an infusion pump, previous and later administration of oral prednisolone.

A single dose of 1.1×10^{14} vg (viral genomes)/kg is administered as an infusion over 60 minutes.

She remained hospitalized for 5 days with subsequent monitoring of liver function tests and hematic biometry, as well as vital signs under the supervision of a pediatric intensive care physician. No complications occurred.

The patient showed improvement in muscle strength with better cephalic control.

The Chop Intend Scale was 45 after treatment with improvement (Fig. 2).

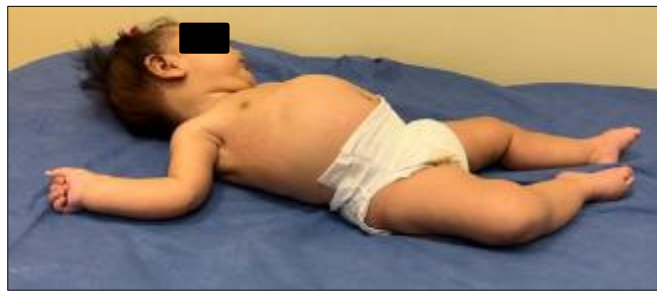

Figure 1 Before treatment

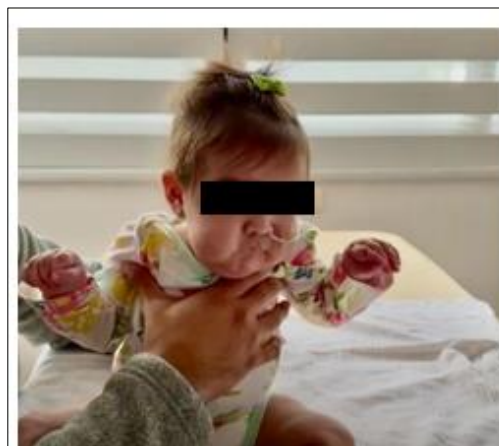

Figure 2 After treatment

2.1. Clinical case 2

6-month-old boy, with normal pregnancy, obtained by natural childbirth, without complications. He is brought to the consultation due to neurodevelopmental delay and hypotonia at four months of age. On neurological examination, expressive facies, with visual tracking and social smile, lingual fasciculations, hypotonia, and weakness of the 4 extremities predominantly proximal, with Daniels Scale 3/5 muscle strength, as well as areflexia, were detected. His breathing was with thoraco-abdominal dissociation, without oxygen requirement.

Genetic testing for MLPA was requested, resulting in 0 copies of the exon 7 SMN1 gene, 1 copy of the exon 8 SMN1 gene, and 3 copies of the SMN2 gene. He was diagnosed with spinal muscular atrophy type 1 due to the onset of symptoms and genetic confirmation at five months of age.

Subsequently, anti-AAV9 antibodies were requested; they were negative with a titer <1:50. Normal liver function tests and blood counts were taken.

The Chop Intend Scale was 37 (moderate grade) before treatment (Fig. 3).

Onasemnogene abeparvovec, also known as Zolgensma®, is applied at six months of age, in the operating room, in a sterile environment, during one hour with an infusion pump, previous and later administration of oral prednisolone.

A single dose of 1.1×10^{14} vg (viral genomes)/kg is administered as an infusion over 60 minutes.

He remained hospitalized for 5 days with subsequent monitoring of liver function tests and hematic biometry, as well as vital signs under the supervision of a pediatric intensive care physician. No complications occurred.

The patient showed improvement in muscle strength.

The Chop Intend scale was 42 after treatment with improvement (Fig. 4).

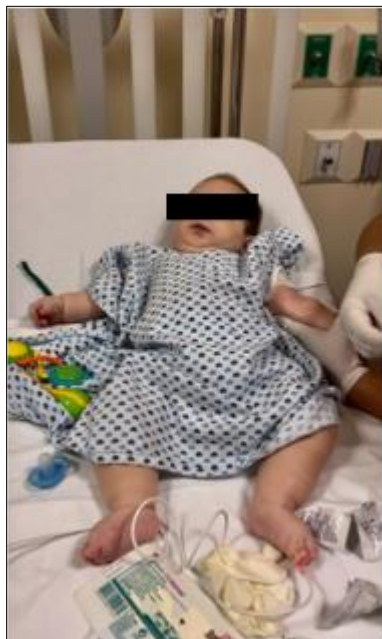

Figure 3 Before treatment

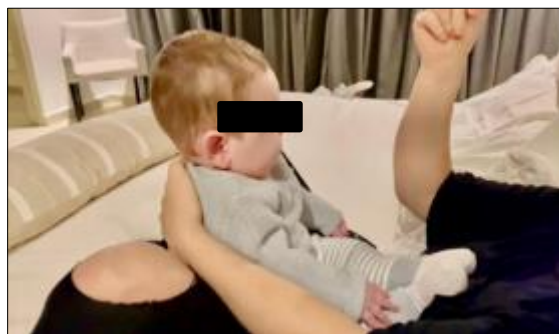

Figure 4 After treatment

3. Conclusion

SMA is a genetic disease that causes weakness and wasting in the voluntary muscles of infants and children and, more rarely, in adults.

It is an autosomal recessive disorder in the survival motor neuron 1 gene, SMN1, that causes a loss of specialized nerve cells, termed alpha motor neurons that control muscle movement.

The diagnosis of SMA can be confirmed with molecular genetic testing with targeted mutation analysis.

When untreated, it will result in severe limitations to motor function, some degree of ventilatory support, and reduced life expectancy.

Gene therapy is an experimental approach that uses imported genes to treat disorders that result from genetic mutations.

The active substance in Zolgensma® contains a functional copy of the SMN1 gene.

This is a first experience with Onasemnogene abeparvovec (Zolgensma®) in a private hospital in Mexico.

The girl patient had a better improvement in motor progression according to Chop Intend Scale, with fewer copies in SMN2. However, Zolgensma® was applied at an earlier age, compared to the boy patient.

Adverse events associated with this gene therapy include local injection reactions, nausea, ALT elevations, and hypersensitivity reactions, which did not occur in our patients.

Finally, it is more cost-effective than comparable therapies and requires less time for treatment.

Compliance with ethical standards

Disclosure of conflict of interest

The authors declare no conflicts of interest.

Statement of ethical approval

All subjects gave their informed consent for inclusion before they participated in the study. The study was conducted by the Declaration of Helsinki, and the protocol was approved by the Ethics Committee.

Statement of informed consent



Informed consent was obtained from all individual participants included in the study.

References

- [1] Dabbous O, Maru B, Jansen JP, et al. Survival, motor function, and motor milestones: comparison of AVXS-101 relative to nusinersen for the treatment of infants with spinal muscular atrophy type 1. *Adv Ther.* 2019; 36:1164–1176.
- [2] Ross LF, Kwon JM. Spinal muscular atrophy: past, present, and future. *Neoreviews.* 2019; 20:0–51.
- [3] Chaytow H, Huang YT, Gillingwater TH, Faller KM. The role of survival motor neuron protein (SMN) in protein homeostasis. *Cell Mol Life Sci.* 2018; 75:3877–3894.
- [4] Chand D, Mohr F, McMillan H, et al. Hepatotoxicity following administration of onasemnogene abeparvovec (AVXS-101) for the treatment of spinal muscular atrophy. *J Hepatol.* 2021; 74:560–566.
- [5] Lowes LP, Alfano LN, Arnold WD, et al. Impact of age and motor function in a phase 1/2A study of infants with SMA type 1 receiving single-dose gene replacement therapy. *Pediatr Neurol.* 2019; 98:39–45.

- [6] Calucho M, Bernal S, Alías L, et al. Correlation between SMA type and SMN2 copy number revisited: An analysis of 625 unrelated Spanish patients and a compilation of 2834 reported cases. *Neuromuscul Disord.* 2018; 28:208–215.
- [7] Souza PV, Pinto WB, Ricarte A, et al. Clinical and radiological profile of patients with spinal muscular atrophy type 4. *Eur J Neurol.* 2021; 28:609–619.
- [8] Arnold WD, Kassar D, Kissel JT. Muscle Nerve. Spinal muscular atrophy: diagnosis and management in a new therapeutic era. *Muscle Nerve.* 2015; 51:157–167. [
- [9] Kirschner J, Butoianu N, Goemans N, et al. European ad-hoc consensus statement on gene replacement therapy for spinal muscular atrophy. *Eur J Paediatr Neurol.* 2020; 28:38–43.
- [10] Lin CW, Kalb SJ, Yeh WS. Delay in diagnosis of spinal muscular atrophy: a systematic literature review. *Pediatr Neurol.* 2015; 53:293–300.
- [11] Malone DC, Dean R, Arjunji R, et al. Cost-effectiveness analysis of using onasemnogene abeparvocec (AVXS-101) in spinal muscular atrophy type 1 patients. *J Mark Access Health Policy.* 2019; 7:1601484.
- [12] Glanzman, A. M., Mazzone, E., Main, M., Pelliccioni, M., Wood, J., Swoboda, K. J., ... Finkel, R. S. The Children’s Hospital of Philadelphia Infant Test of Neuromuscular Disorders (CHOP INTEND): Test development and reliability. *Neuromuscular Disorders,* 2010; 20(3), 155–161.

Authors short Biography

	<p>José Antonio Infante Cantú Pediatric neurologist graduated from Instituto Nacional de Pediatría in Mexico and from Universidad Autonoma de Nuevo Leon, Mexico.</p> <p>Pediatric neurologist attached to Tecnológico de Monterrey, Zambrano Hellion Hospital, Tec Salud.</p> <p>Ex-president of the Mexican Society of Pediatric Neurology, and Nuevo Leon Pediatrics College.</p> <p>Coordinator of Epilepsy Clinic in Tecnológico de Monterrey, Zambrano Hellion Hospital, Tec Salud.</p> <p>An active member of the Mexican Academy of Neurology, Mexican Society of Pediatric Neurology, and Mexican Chapter of the International League against Epilepsy.</p>
	<p>Sofía Lucila Rodríguez Rivera Pediatric neurologist graduated from La Raza National Medical Center IMSS UNAM.</p> <p>Pediatric neurologist attached to Tecnológico de Monterrey, Zambrano Hellion Hospital, Tec Salud, and the General Hospital of Zone No. 33 of the Mexican Social Security Institute (IMSS) Monterrey, Nuevo León.</p> <p>Epileptologist from the University of Murcia, Spain.</p> <p>Neurophysiologist from the Arturo Jauretche National University, Buenos Aires, Argentina.</p> <p>An active member of the Mexican Academy of Neurology, Mexican Society of Pediatric Neurology, and Mexican Chapter of the International League against Epilepsy.</p>